



## Summary Feedback

(Combined feedback broadcasted multiple time this week)

### **PRE-RECORDED: Basildon FRCR 2B 'A to Zee' Course 2020**

## **Session 35/36**

### **MSK for FRCR**

#### **(1) How to Report MRI Shoulder**

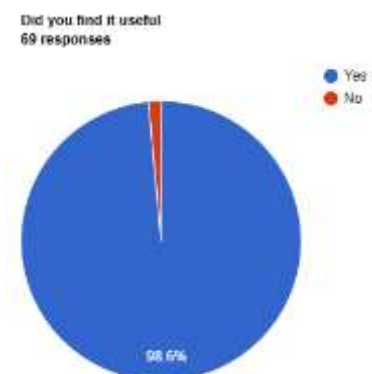
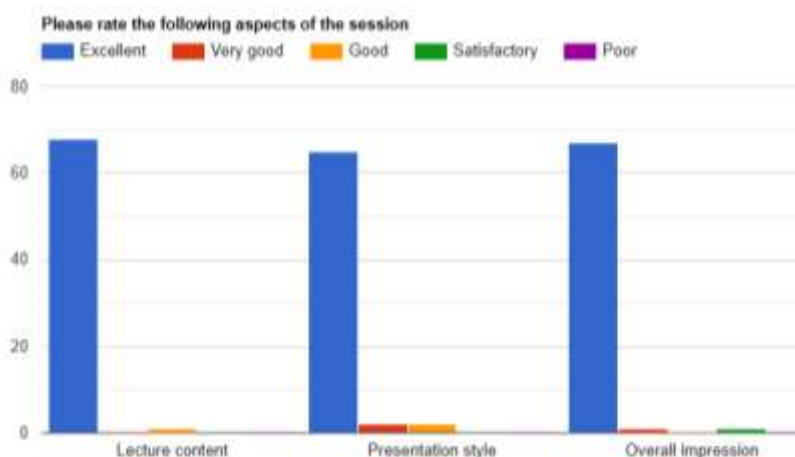
#### **(2) Exam Viva Cases**

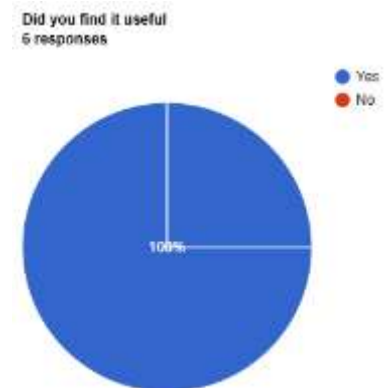
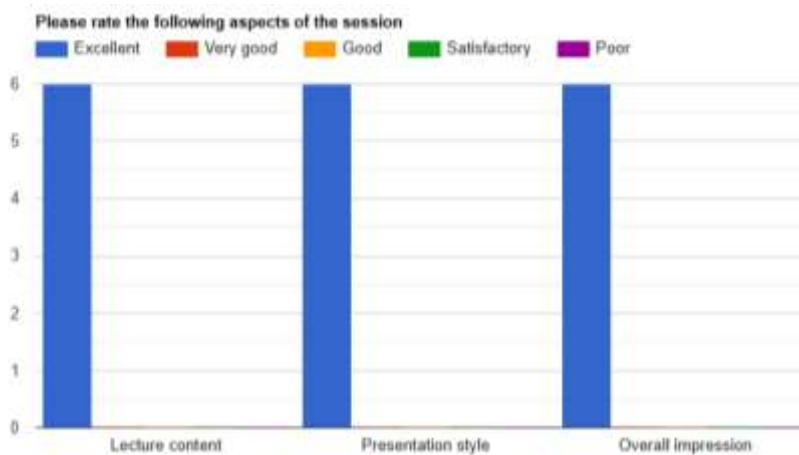
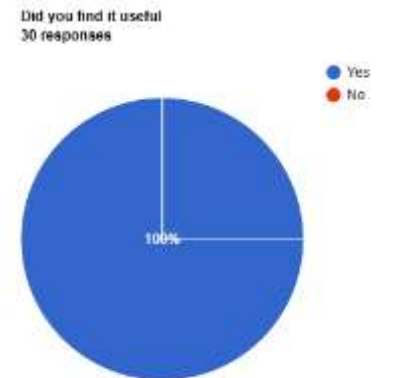
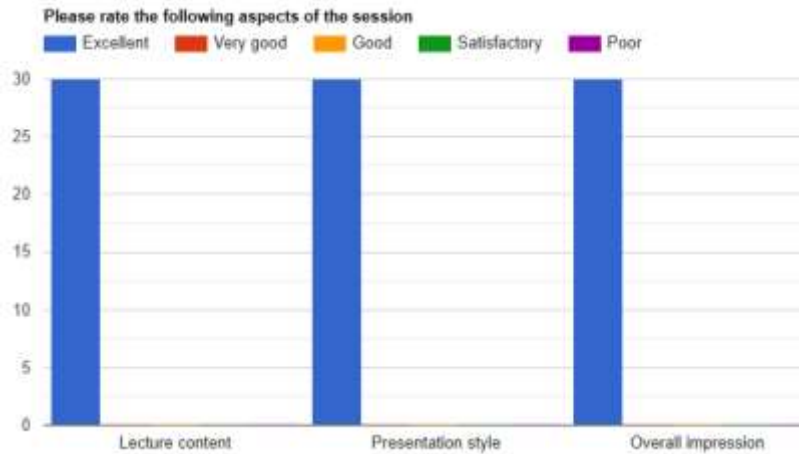
**(13<sup>th</sup> & 14<sup>th</sup> December 2025)**

**Lecturers: Sajid Butt & Sami Khan**

### **Summary Points:**

- Total Attendees: 360 from 35 Countries (Algeria, Austria, Bahamas, Bangladesh, Canada, Dominica, Egypt, Ghana, Hong Kong, India, Indonesia, Iran, Iraq, Jordan, Kenya, Malaysia, Malta, Myanmar, Nepal, Nigeria, Norway, Oman, Pakistan, Saudi Arabia, Singapore, South Africa, Sri Lanka, Sudan, Thailand, Türkiye, UAE, UK, Ukraine, Yemen, Zimbabwe).
- Total duration: 3 hours (each session broadcasted thrice during the week)
- Total feedback received from 105 participants, from three different broadcasts



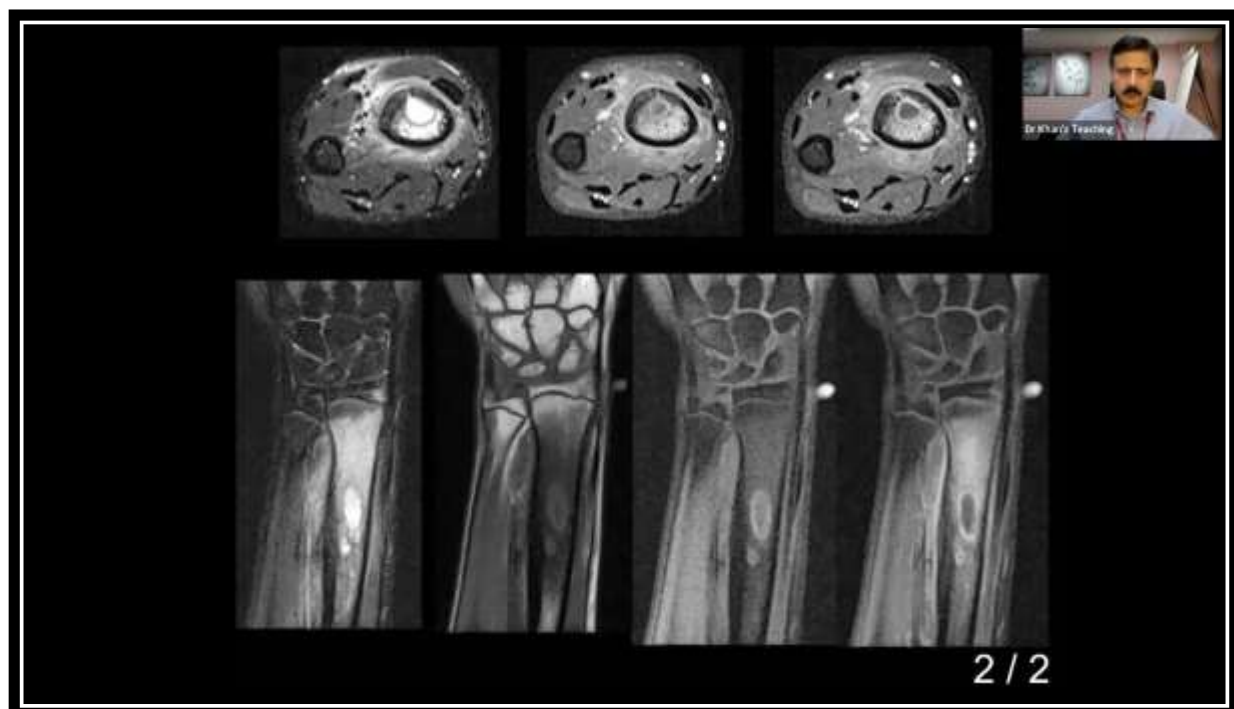
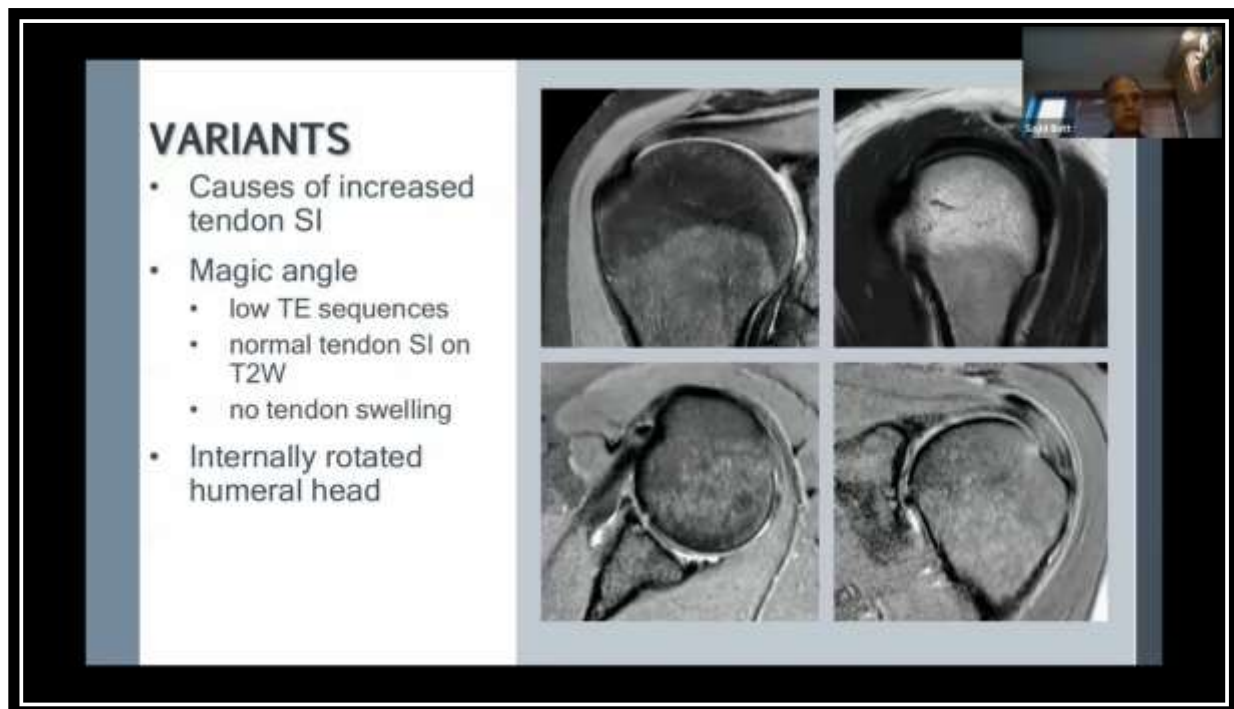


## Testimonials

- Very useful and interesting session simplifying shoulder joint MRI going through FRCR needed and beyond, very useful for the exam as well as real life practice, together with brilliant viva cases, many thanks (Egypt).
- I really struggle with MSK radiology and have found this session incredibly insightful, I really like the explanation of each condition and the key concepts that need to be applied in the exam setting. Very enjoyable session (UK).
- Very extensive session on shoulder MRI, all aspects covered by Dr. Sajid Butt. Brilliant teaching by Dr. Sami Khan. Big thank you (Pakistan).
- Very in-depth teaching on how to approach the MRI shoulder interpretation (Malaysia).
- Lecture targeting day to day reporting are very essential for us. Kindly add more lectures like this especially wrist ankle and elbow joints (UAE).
- Shoulder MRI was well done. Perfect analysis of shoulder pathology. Muscular MRI cases were interesting as well (UK).
- As in the previous one as well, it is really useful to get a good overview how to do a thorough review of a joint (Austria).
- Every aspect of the session was useful; the cases, the gentle teaching style (Nigeria).


- I especially liked the last viva part, it was excellent. But shoulder MRI was also great! (UK).
- The distinction between osteomyelitis and Ewings was very helpful. Lecture on the shoulder joint MRI was also useful (Saudi Arabia).
- Well-organized session full of knowledge (Sudan).
- Detailed pathology with background normal anatomy was useful (Uk).
- All the aspects of the lecture were useful (UK).
- Excellent systematic approach interpreting MRI shoulder (Sudan).
- Great session (Libya).
- Clear understanding of rotator cuff tear (Pakistan).
- Excellent lecture content (UAE).
- Excellent teaching as always (UK).
- Brilliant and super useful, as always (UAE).
- Wonderful talk (Sudan).
- Very educative (UK).
- An excellent and impactful teaching session (Nigeria).
- Excellent lecture and teachers (Nigeria).
- Awesome (Indonesia).
- Excellent presentation and really good cases (Austria).
- Very very good (UAE).
- All of the aspects were useful (Iraq).
- Content and delivery were excellent (UK).
- I liked him talking through relevant MRI images (UK).
- Practical and pertinent to my daily practice (UAE).
- All the aspects were excellent (UK).
- In depth teaching about MRI shoulder (Pakistan).
- Very helpful (Pakistan).
- Awesome (Indonesia).
- Amazing explanation (UK).
- Excellent cases presentation (Nigeria).
- I liked the thorough description and cases (UAE).
- All of it was useful (Egypt).
- Relevant to my usual practice (UAE).
- Excellent teaching session (Pakistan).
- Excellent case discussions (India).
- It's all useful (UAE).
- Wonderful slides. Thank you (Pakistan).
- Complex shoulder anatomy and its pathologies were well taught (Pakistan).
- Assessment of rotator interval and anterior instability were very useful (Sudan).
- Very beneficial (Pakistan).
- Detailed shoulder MRI lecture was useful (UK).
- Excellent teaching by the moderator (UK).
- Cases and teaching were useful (Sri Lanka).
- It was perfect (UAE).
- The leading questions were excellent (India).
- Very informative session (Algeria).
- Viva session with excellent explanations was useful (UK).
- Excellent teaching (UK).

- I liked the MRI examples, the images were clear (Pakistan).
- Great teaching (Pakistan).
- Brilliant as usual (UAE).
- Excellent, excellent, excellent (Pakistan).
- Excellent!!!! (UK).

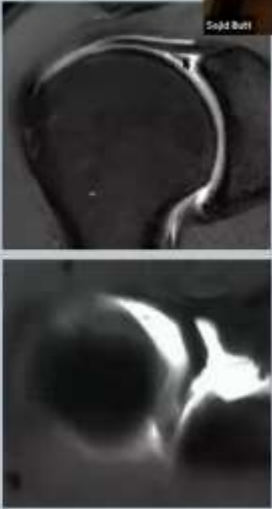


### SLAP TYPE 3

- Bucket-handle tear
- Central portion of labrum displaced into the joint
- No involvement of biceps anchor



Modarresi et al. AJR 2003



=====XX=====XX=====